Efficient immunohistochemical differential diagnosis of undifferentiated neoplasia

ZYTOMED SYSTEMS

Conventional histomorphology: pleomorph and/or high-grade spindle-cell

Localisation of tumour infiltrates	Antibody panel	Marker constellation and valuation
Central nervous system	CK8/18, Ber-EP4, GFAP, Melan A, CD34	CK8/18 + (diffuse), Ber-EP4 +/-, GFAP -/+ (focal) ▶ carcinoma metastasis if plexus carcinoma has been excluded
		GFAP +, CK8/18 -/+ (focal), CD34-positive microvascular proliferates ▶ glioblastoma
		Melan A + ▶ malignant melanoma (metastasis)
Lymph node	Pan-CK, S100, CD30, CD20, kappa/lambda	Pan-CK + (diffuse or focal, other markers negative) ▶ carcinoma metastasis
		S100 + (diffuse nuclear and cytoplasmic) ▶ metastasis of malignant melanoma
		kappa/lambda +, CD20 - ▶ immature (anaplastic) plasmocytoma (myeloma)
		CD30 + (diffuse membrane-associated and in the Golgi region), Pan-CK -/+ (focal), CD20 - ▶ anaplastic large-cell lymphoma (ALCL)
		CD20 +, CD30 +/- ▶ diffuse large-cell B-cell lymphoma, anaplastic variation
		all markers negative ▶ carcinoma with loss of CK expression or histiocytic sarcoma?
Gastrointestinal tract, genito-urinary system, parenchymatous organs, head/neck area	Pan-CK, S100, HMB45, CD30, CD20	Pan-CK + (diffuse or focal, other markers negative) ▶ (sarcomatoid) carcinoma
		S100 + (diffuse nuclear and cytoplasmic), HMB45 +/- ▶ malignant melanoma
		CD30 + (diffuse membrane-associated and in the Golgi region), Pan-CK -/+ (focal), CD20 - ▶ anaplastic large-cell lymphoma (ALCL)
		CD20 +, CD30 +/- ▶ diffuse large-cell B-cell lymphoma, anaplastic variation
		all markers negative ▶ carcinoma with loss of CK expression?
Skin	Pan-CK, CKS/6, CD31, S100, CD30, h-Caldesmon	Pan-CK+/-, CK5/6 +/-, CD31 -, h-Caldesmon -, S100 -/+ (focal) ▶ (sarcomatoid) carcinoma, differential diagnosis metastasis
		S100 + (diffuse nuclear and cytoplasmic) ▶ (spindle-cell) malignant melanoma
		CD31 + ▶ angiosarcoma
		h-Caldesmon + (more than few cells) ▶ leiomyosarcoma
		CD30 + (diffuse membrane-associated and in the Golgi region), Pan-CK -/+ (focal) ▶ (sarcomatoid) anaplastic large-cell lymphoma
		all markers negative ▶ atypical fibroxanthoma (head/neck, actinic lesion?)
Soft tissue	S100, HMB45, Myf4, CD31, h-Caldesmon, CD30	S100 + (diffuse nuclear and cytoplasmic), HMB45 + ▶ malignant melanoma, differential diagnosis clear cell sarcoma (if HMB45 -: differential diagnosis malignant peripheral nerve sheath tumour, MPNST)
		CD31 + ▶ angiosarcoma
		Myf4 + (nuclear, attention: immunoreactivity in regenerative skeletal muscle fibres in tumour-infiltrated areas) ▶ pleomorphic rhabdomyosarcoma or other tumour with focal rhabdomyoblastic differentiation
		h-Caldesmon + (more than few cells) ▶ pleomorphic leiomyosarcoma
		CD30 + (diffuse membrane-associated and in the Golgi region) ▶ (sarcomatoid) anaplastic large-cell lymphoma
		other marker combination ▶ sarcoma; needs further investigation

Conventional histomorphology: epitheliod, intermediate-cell to large-cell

Localisation of tumour infiltrates	Antibody panel	Marker constellation and valuation
Pleura	p63, WT1, Podoplanin (D2-40), S100, Pan-CK	p63 +, WT1 -, D2-40 (Podoplanin) -/+ ▶ pleura carcinosis due to non-keratinising squamous cell carcinoma
		WT1 + and/or D2-40 (Podoplanin) +, p63 -, Pan-CK + ▶ epithelioid or biphasic mesothelioma, Attention: Pleura carcinosis due to serous ovarian carcinoma
		Pan-CK +, other markers negative ▶ Pleura carcinosis due to macrocellular carcinoma
		S100 + (diffuse nuclear and cytoplasmic), Pan-CK -/+ (focal) ▶ metastasis of a malignant melanoma
Peritoneum	Ber-EP4, Pan-CK, Calretinin, S100, HMB45, Inhibin α	Ber-EP4 + or Ber-EP4 -, Pan-CK +, Calretinin - ▶ peritoneal carcinosis
		Calretinin +, Pan-CK +, Ber-EP4 - ▶ epithelioid or biphasic mesothelioma,
		S100 + (diffuse nuclear and cytoplasmic), Pan-CK -/+ (focal), Ber-EP4 -, Inhibin α - ▶ metastasis of a malignant melanoma
		Inhibin α +, Calretinin +, Ber-EP4 -, S100 -/+ (focal) ▶ granulosa-cell tumour?
		HMB45 +, S100 - ▶ perivascular epithelioid-cell tumour
Central nervous system	CK8/18, GFAP, Melan A, OCT4, CD117	CK8/18 + (diffuse), GFAP -/+ (focal) ▶ carcinoma metastasis if plexus carcinoma has been excluded
		GFAP +, CK8/18 -/+ (focal) ▶ anaplastic glioma or glioblastoma
		Melan A + ▶ malignant melanoma (metastasis)
		OCT4 +, CD117 - ▶ embryonary carcinoma
		OCT4 +, CD117 + ▶ germinoma
Lymph node	Pan-CK, CD20, S100, OCT4, CD30	Pan-CK + (diffuse), OCT4 - ▶ carcinoma metastasis
		S100 + (diffuse nuclear and cytoplasmic), Pan-CK -/+ (focal) ▶ metastasis of a malignant melanoma
		OCT4 +, Pan-CK + (diffuse), CD30 + ▶ metastasis of an embryonary carcinoma
		OCT4 +, Pan-CK -/+ (diffuse), CD30 - ▶ metastasis of a seminoma
		CD30 + (diffuse membrane-associated and in the Golgi region), Pan-CK -/+ (focal), CD20 - ▶ anaplastic large-cell lymphoma, „small-cell" variant
		CD20 + ▶ diffuse large-cell B-NHL
Ovary	Pan-CK, EMA, S100, Inhibin α, OCT4, CD20	Pan-CK +, EMA +/-, Inhibin α -, OCT4 - ▶ carcinoma (primary tumour or metastasis)
		S100 + (diffuse nuclear and cytoplasmic), Pan-CK -/+ (focal), Inhibin α - ▶ malignant melanoma
		Inhibin α +, EMA -, S100 -/+ (focal) ▶ germ band or stroma tumour
		OCT4 +, Pan-CK + (diffuse) ▶ embryonary carcinoma
		OCT4 +, Pan-CK -/+ (focal) ▶ dysgerminoma
		CD20 + ▶ diffuse large-cell B-NHL
Gastrointestinal tract, Respiratory tract, genito-urinary system, parenchymatous organs, head/neck area	Pan-CK, S100, HMB45, CD20, CD30, kappa/lambda	Pan-CK + (diffuse) ▶ carcinoma
		S100 + (diffuse nuclear and cytoplasmic), Pan-CK -/+ (focal), Inhibin α - ▶ malignant melanoma, (if HMB45 -: differential diagnosis epithelioid malignant nerve sheath tumour)
		HMB45 +, S100 - ▶ perivascular epithelioid-cell tumour
		CD20 + ▶ diffuse large-cell B-NHL
		CD30 + (diffuse membrane-associated and in the Golgi region), Pan-CK -/+ (focal), CD20 - ▶ anaplastic large-cell lymphoma, „small-cell" variant
		Kappa/lambda +, CD20 - ▶ plasmoblastic lymphoma? (HIV + ?), ALK-1-positive diffuse large-cell B-NHL?
Soft tissue	Pan-CK, S100, CD31, HMB45, CD117	Pan-CK + (diffuse) ▶ epithelioid sarcoma, differential diagnosis carcinoma metastasis
		S100 + (diffuse nuclear and cytoplasmic), HMB45 +/- ▶ malignant melanoma, differential diagnosis clear-cell sarcoma (if HMB45 -: differential diagnosis epithelioid malignant nerve sheath tumour)
		HMB45 +, S100 - ▶ perivascular epithelioid-cell tumour
		CD31 + ▶ epithelioid angiosarcoma
		CD117 + ▶ epithelioid gastro-intestinal stroma tumour (GIST)?

Conventional histomorphology: small-cell

Localisation of tumour infiltrates	Antibody panel	Marker constellation and valuation
Central nervous system	CK8/18, GFAP, Melan A, TTF-1, Synaptophysin	CK8/18 + (diffuse), Synaptophysin +, TTF-1 +/- ▶ metastasis of a small-cell carcinoma
		GFAP +, CK8/18 -/+ (focal), Synaptophysin - ▶ small-cell fraction of a glioblastoma
		Melan A + ▶ small-cell malignant melanoma (metastasis)
other localisation	Pan-CK, S100, CD99, Desmin, Synaptophysin, TdT, Myeloperoxidase (MPO), CK20	Pan-CK + (diffuse), Desmin -, CK20 -, Synaptophysin +/- ▶ small-cell carcinoma (if Synaptophysin –: differential diagnosis small-cell squamous cell carcinoma)
		CK20 + (punctual perinuclear), Synaptophysin + ▶ Merkel cell carcinoma
		CD99 + (diffuse membrane-associated), Pan-CK -/+ (focal), Synaptophysin +/-, TdT -, S100 -/+ (focal), MPO - ▶ PNET
		Synaptophysin +, CD99 -, Pan-CK -, S100-positive sustentacular cells ▶ olfactory neuroblastoma? (rhinopharynx)
		S100 + (diffuse nuclear and cytoplasmic) ▶ small-cell malignant melanoma
		Pan-CK+/-, Desmin + (point-shaped), CD99 -/+, TdT- ▶ desmoplastic small- and round-cell tumour?
		TdT +, CD99 +/-, Pan-CK -, MPO - ▶ lymphoblastic lymphoma/leukaemia, NK cell lymphoma
		MPO + ▶ myeloid sarcoma

Markers for immunohistochemical diagnostics of CUP (Carcinoma of Unknown Primary)

Marker	Predicted localisation of primary tumour	Type of carcinoma	Comments
Arginase-1	liver	HCC (Hepato Cellular Carcinoma)	more specific than HePar1 and Glypican-3
CDX-2	colorectum, ovary, bladder (diffuse immunoreactivity)	adenocarcinomas (ovary only in case of gastrointestinal mucinous differentiation)	adenocarcinoma of stomach, oesophagus, pancreas, and biliary ducts frequently show heterogeneous immunoreactivity. Adenocarcinomas of the lung are rarely positive. (mainly mucinous carcinoma)
CK7/CK20	colorectum	adenocarcinomas (CK7-/CK20+)	
DPC4/SMAD4	pancreas, biliary ducts	adenocarcinomas	only the loss of expression is relevant for diagnosis!
GATA3	breast, urinary tract	adenocarcinomas	more sensitive for mamma as GCDFP-15 and Mammaglobin in poorly differentiated tumours, but less specific; among others mesothelioma and ductal pancreas carcinoma
GCDFP-15	breast	adenocarcinomas	high specificity but low sensitivity in poorly differentiated tumours; rare immunoreactivity in lung
Glypican-3	liver	HCC (Hepato Cellular Carcinoma)	positive in malignant melanomas, in a minority of squamous cell carcinoma, and in yolk sack tumours (> 90%); otherwise more sensitive and specific than HepPar1
HepPar1	liver	HCC (Hepato Cellular Carcinoma)	positive in appr. 50% of all adenocarcinomas of stomach and to a lesser degree in other primary localisations (colon, lung, pancreas); therefore minor positive predictive value for differentiation from HCC and liver metastases.
Mammaglobin	breast, endometrium	ductal/lobular carcinomas, endometrial adenocarcinomas	high specificity, but low sensitivity in poorly differentiated breast carcinoma
NKX3.1	prostate	adenocarcinomas	high specificity and sensitivity; positive in some PSA-neg., poorly differentiated adenocarcinomas.
Estrogen Receptor	mamma, ovary, corpus uteri	adenocarcinomas	negative in mucinous carcinomas of the ovary and serouse corpus carcinoma
Pax-8	kidney, ovary, uterus, thyroid gland	carcinoma of the kidney (all types), mullerian tumours; thyroid carcinoma (including medullary)	lower sensitivity in mucinous ovary carcinomas; more sensitive than Thyreoglobulin in insular and anaplastic carcinomas of the thyroid; mesothelioma negative
SATB2	colon	adenocarcinomas	more specific than CDX-2, larger proportion of stained medullary carcinoma
PSA	prostate	adenocarcinomas	
Thyreoglobulin	thyroid gland	differentiated and insular thyroid gland carcinomas	lower sensitivity in insular carcinomas
TTF-1 **nuclear** (only clone 8G7G3/1, other clones mostly less specific	lung, thyroid gland	adenocarcinomas (non mucinous), large-cell non-neuroendocrine carcinomas; insular and medullar thyroid carcinomas	with clone 8G7G3/1 also rare immunoreactivity in endometrial adenocarcinomas. expression in small cell carcinomas is not location specific
Uroplakin II	urinary tract	urothelial carcinoma	very specific, more sensitive than Uroplakin III
WT1 **nuclear**	ovary	serous adenocarcinoma	mesotheliomas and mucinous mamma carcinomas are positive; serous corpus carcinoma are negative
Lokalisation of the primary of neuroendocrine tumours (NET), G1 and G2			
CDX-2	midgut (ileum, appendix, colon)	NET G1/2	
NKX6.1	pancreas, duodenum	NET G1/2	alternative to polyclonal Pax-8
Pax-8 **polyklonal**	pancreas, duodenum	NET G1/G2	due to cross reactivity to Pax-6
TTF-1 **nuclear**	lung	carcinoid	

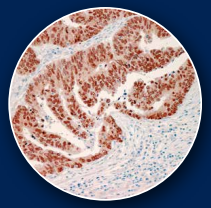
CDX-2, liver metastasis of colon carcinoma

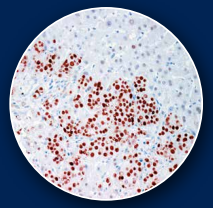
Estrogen Receptor, liver metastasis of breast carcinoma

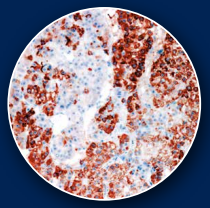
HepPar1, hepatocellular carcinoma

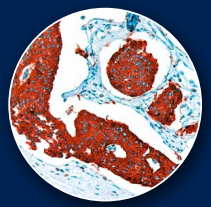
Synaptophysin, neuroendocrine tumour

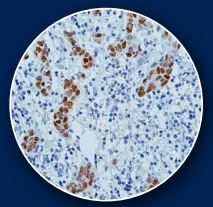
GATA3, breast carcinoma

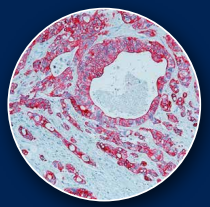
Cytokeratin 20, colon carcinoma

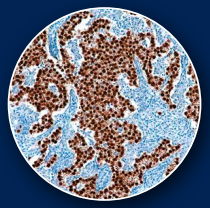
Oct-4, seminoma

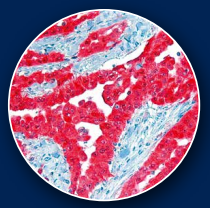
Calretinin, mesothelioma

TTF-1, pulmonary adenocarcinoma